

EDUCATIONAL MOMENTS®



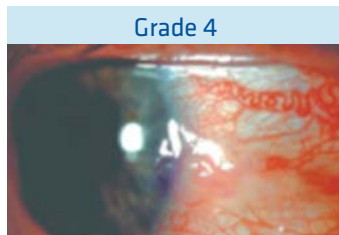
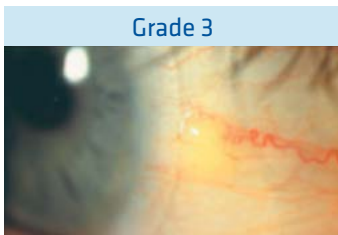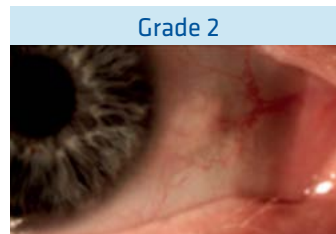
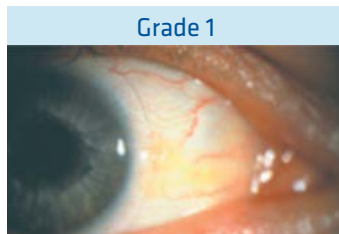
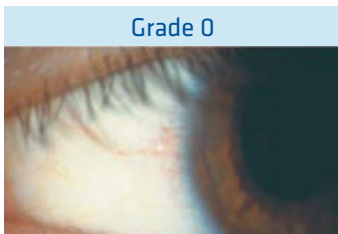
How to manage patients with pinguecula

WHAT YOU NEED TO KNOW

Slit Lamp Viewing:

1. Diffuse beam
2. Medium magnification (16x)
3. Direct illumination

Grading:



- Grade 0: None visible
 - Grade 1: Slightly raised area <0.5mm
 - Grade 2: Slightly raised area 0.5 – 2.5mm
 - Grade 3: Raised yellow area
 - Grade 4: Unsightly
- Position: Nasal / Temporal

Incidence:

- Unknown, increases with age
- Not CL related, although may be aggravated by lens edge

Aetiology:

- Degenerative sub-epithelial collagen often associated with calcification
- Associated with excessive exposure to hot, dry, windy climates and UV radiation

Symptoms:

- Typically none although may cause dryness and discomfort with CL wear.

Signs:

- Raised yellowish nodule on bulbar conjunctiva (nasally or temporal adjacent to limbus).
- If cornea involved, becomes pterygium.

EDUCATIONAL MOMENTS®



How to manage patients with pinguecula

WHAT YOU NEED TO RECOMMEND TO YOUR PATIENTS

Recommendations:

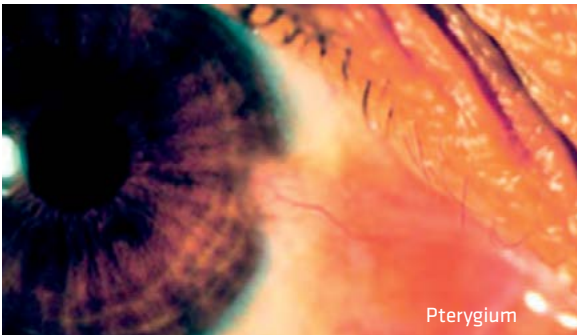
- Not a contraindication for CL wear
- Avoid mechanical disturbance for comfort reasons
- Ocular lubricants can be helpful
- Use of UV protection with wrap around sunglasses to prevent further deterioration



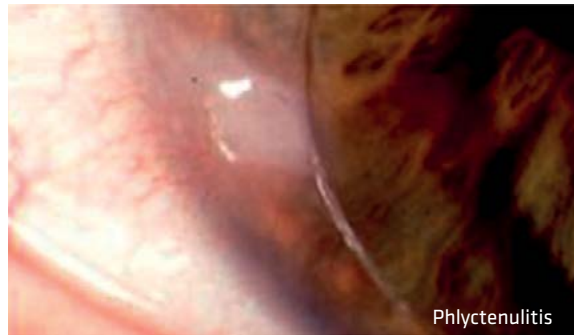
Prognosis:

- Generally remains constant, not affected by contact lens wear
- If inflamed may require medical treatment

Differential Diagnosis:



Pterygium



Phlyctenulitis

Phlyctenulitis - chronic inflammatory complication resulting in elevated, semi-opaque epithelial lesion at limbus with conjunctival hyperaemia, corneal staining and neovascularisation; secondary to allergic response or due to rigid lens design (also known as Vascularised Limbal Keratitis VLK)

This series is adapted from A Handbook of Contact Lens Management (3rd Edition) published by THE VISION CARE INSTITUTE®

HOW TO FIND OUT MORE

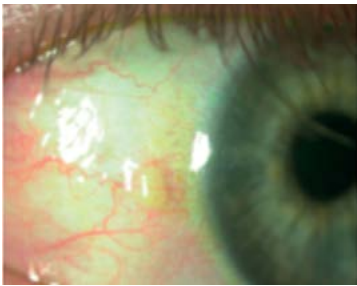
- Click [here](#) for a general refresher on slit lamp techniques
- Click [here](#) to watch our educational video on slit lamp examination using diffuse illumination
- Click [here](#) for our guide to the cumulative effects of UV on the eye
- Click [here](#) to read more about UV ocular protection strategies
- Click [here](#) for a further reading list and references

EDUCATIONAL MOMENTS®



How to manage patients with pinguecula

PATIENT CASE STUDY



Patient RE is a 38-year-old landscape gardener who has worn daily disposable hydrogel lenses for sports and social use only for the past 10 years.

At work he spends long hours out of doors. He visits your practice for the first time for his annual check-up and reports no problems with his lenses.

His current contact lenses have no UV blocker.

Quiz:

1. What slit lamp technique would you use to examine this patient's bulbar conjunctiva?

- A. Sclerotic scatter
- B. Diffuse beam, medium illumination
- C. High magnification
- D. Indirect illumination

2. What grade would you give to his pinguecula?

- A. Grade 1
- B. Grade 2
- C. Grade 3
- D. Grade 4

3. Which of the following environmental conditions are associated with this condition?

- A. Air-conditioned offices
- B. High levels of UV radiation
- C. Cold climates
- D. Humid conditions

4. Which of the following recommendations is likely to be the best option?

- A. Switch to UV-blocking contact lenses
- B. Advise wide-brimmed hat
- C. Recommend wraparound sunglasses
- D. All of these

Correct answers:

- 1: **B.** Use a diffuse beam (right), medium magnification and direct illumination to examine the bulbar conjunctiva.
- 2: **C.** Slit-lamp examination of the bulbar conjunctiva shows a raised yellow area adjacent to the patient's limbus.
- 3: **B.** High levels of UV radiation are associated with pinguecula, along with hot, dry, windy climates.
- 4: **D.** Wraparound sunglasses and UV-blocking contact lenses, plus a wide-brimmed hat, can help protect eyes from UV transmission*.

* UV-absorbing contact lenses are not substitutes for protective UV absorbing eyewear such as UV absorbing goggles or sunglasses as they do not completely cover the eye and surrounding area.

